

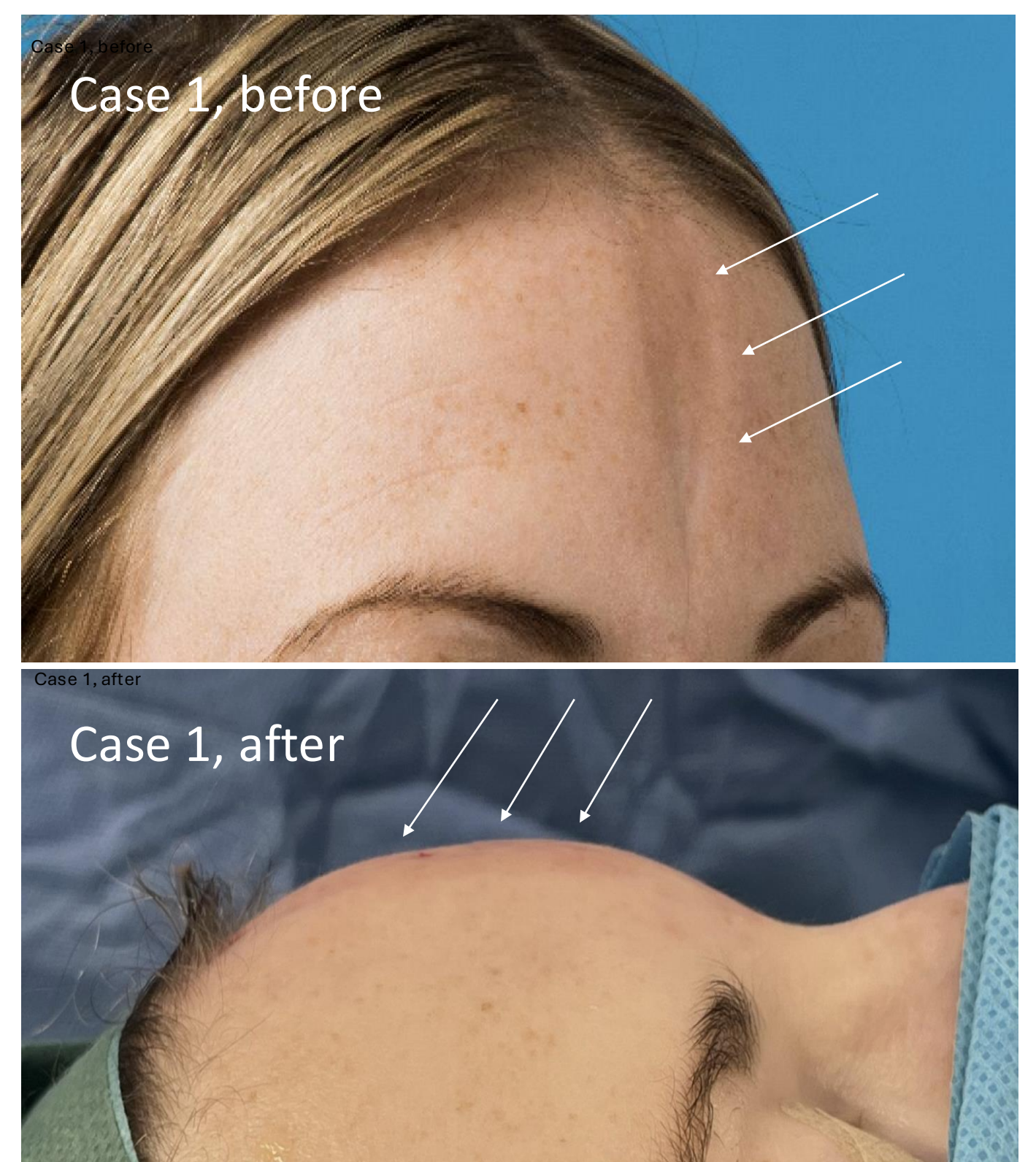# Advancements in the Treatment of Localized Scleroderma (Morphea) and the Role of Injectables: A Comprehensive Overview of Facial Changes Induced by Scleriform Conditions

S. Könniker, J. Watson, B.S. Kim, N. Lindenblatt, P. Giovanoli

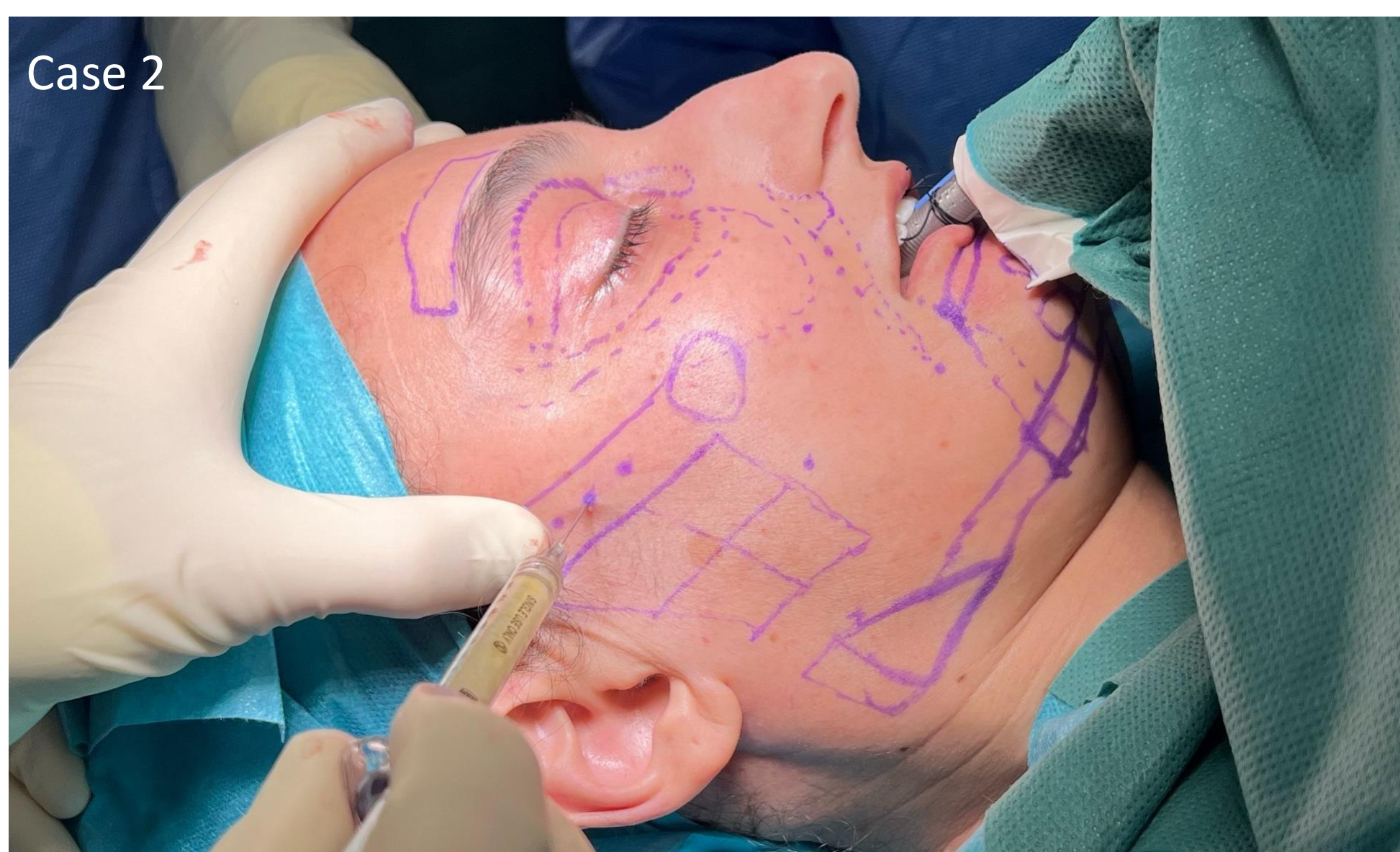**Introduction** Systemic sclerosis/ morphea can have severe impact on quality of life up to major depressive disorder and presents complex challenges in the treatment of facial tissue loss. This highly specific patient population with cutaneous limited systemic sclerosis including soft tissue loss of the face.

## Patient case studies

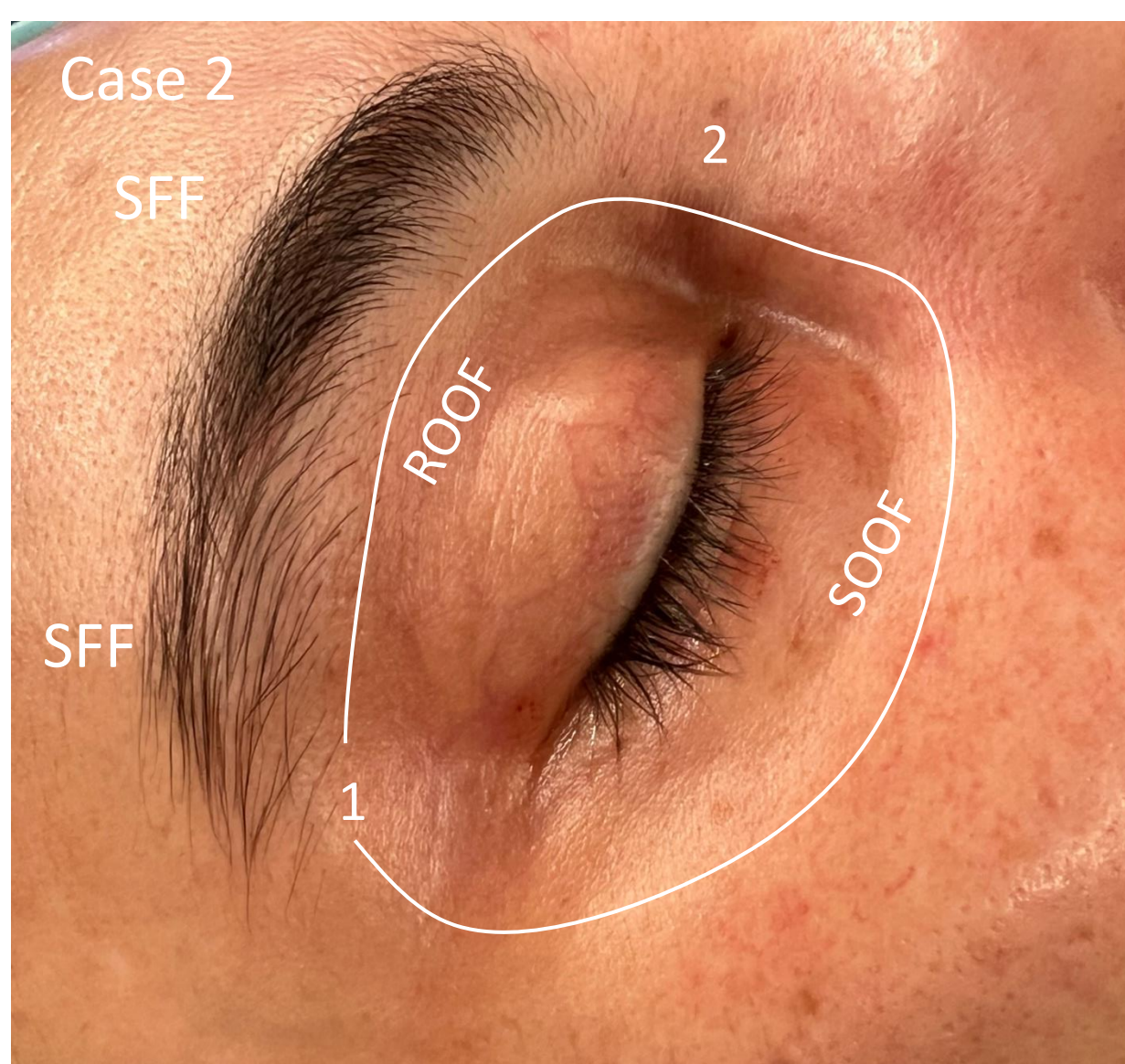
**Case 1** is a 30-year-old female with linear circumscribed scleroderma of the forehead, maintaining a steady state after local corticosteroid treatment. **Case 2** is a 40-year-old female with cutaneous limited systemic sclerosis primarily affecting the periorbital region and causing severe atrophy of the lower third of the face. She is undergoing medication-based immunosuppressive maintenance therapy with monthly infusions of tocilizumab, a monoclonal antibody (biological).



**Before and after images** following two fat grafting sessions and two hydroxyapatite injection treatments



**Complex reconstruction** of the face aesthetic units with 252 ml of microfat over four sessions within 12 months



## Complete

## reconstruction of the periorbital region

Showing 4th fat grafting in Case 2: including circular periosteal fat coverage (1), subfrontal fat (SFF), ROOF, SOOF and the muscle less upper lateral wall of the nose (2)

**Fat grafting** requires repeated applications to sustain its benefits, utilizing the body's natural resources for lasting improvements in affected areas (Case 1, 2).

**Hyaluronic acid fillers** temporarily restore soft tissue volume and are suitable for lip augmentation and tissue expansion prior to fat grafting (Case 2).

**Radiesse®**, enriched with calcium hydroxyapatite microspheres, augments volume and enhances skin quality by stimulating collagen production for atrophic skin (Case 1).

**Conclusion** For the best possible treatment of this highly specific patient population with cutaneous limited systemic sclerosis including soft tissue loss of the face an interdisciplinary approach is essential. Additionally, tissue reconstruction should be performed after achieving a stable disease state induced by medication, without any further progression.

Targeted studies are necessary to develop optimal treatment protocols for this specific patient group.