

Secondary knee extensor tendon reconstruction with gastrocnemius flap associated with achillen tendon : long term functional result

Mauro Maniglio¹, Aurélie Cavin¹, Manon Belhoste¹, Robin Martin², Pietro G. Di Summa¹

¹Department of Plastic, Reconstructive and Hand Surgery, Centre Hospitalier Universitaire Vaudois (CHUV), Lausanne, Switzerland

²Department of Orthopedic Surgery, Centre Hospitalier Universitaire Vaudois (CHUV), Lausanne, Switzerland

Introduction

Acute cases of patellar tendon injuries may be repaired directly or with tendon reinsertion, often using reinforcement like a patellotibial cerclage wire. Chronic injuries or failed repairs may require complex reconstructions. The vascularized gastrocnemius tendon graft can be effective for simultaneous repair and soft tissue correction.

Procedure

After initial debridement, reconstruction is needed if direct suturing cannot maintain patellar height or when soft tissue coverage is inadequate.

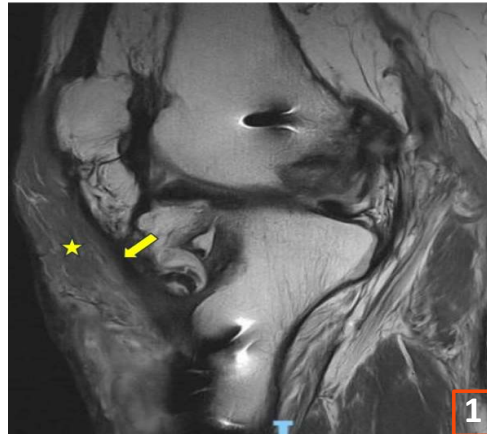
A medial gastrocnemius (MG) flap, preserving its vascular supply and innervation, is used, including its insertion for tendinous reconstruction.

After knee immobilization, gradual flexion and physical therapy for muscle strengthening is conducted over four months. (Fig 2, 3)

Discussion

This technique allows for repair of the extension apparatus, by using the muscle's aponeurosis and, if needed, a portion of the Achilles tendon.

Although literature is limited, existing case reports and series demonstrate the flap's efficacy, especially compared to high failure rates of nonvascularized grafts in extensor mechanism reconstruction.



Case N°1

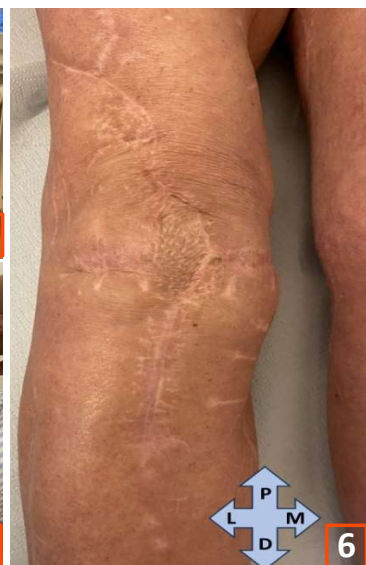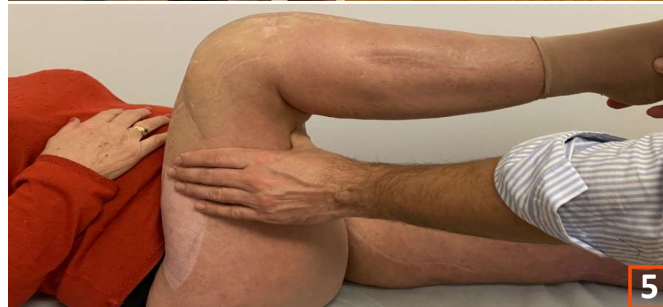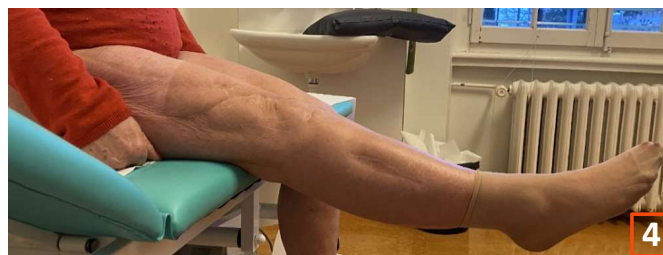
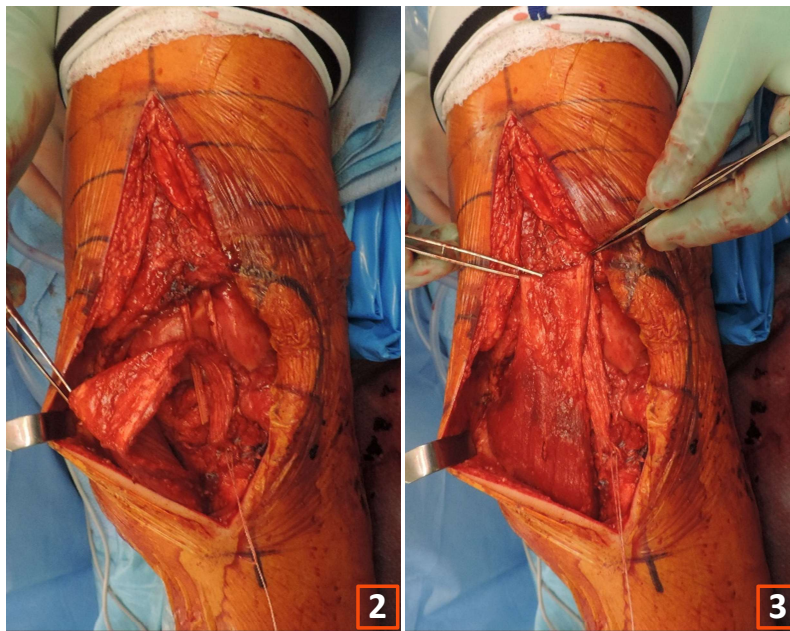
A 74-year-old male with total knee arthroplasty revision experienced a patellar tendon rupture treated with direct transosseous sutures and mesh reinforcement. He then developed a deep infection and benefited from a MG flap and skin graft, resulting in satisfactory knee function after 10 years.

Case N°2

A 65-year-old female suffered a severe open fracture dislocation of her right knee. Achilles tendon allograft reconstruction was carried out but was complicated by dehiscence and infection, resulting in a remaining infrapatellar defect with extensor mechanism deficit. A MG flap and skin graft restored the extensor mechanism and soft tissue coverage, achieving good function after 3 years. (Fig 4, 5, 6) At 3 years follow-up, the MRI showed a reconstructed tendon in full continuity with a vital muscle. (Fig 1)

Case N°3

A 58-year-old male with total loss of the patellar tendon after infectious bursitis underwent reconstruction with a folded MG tendon flap, achieving functional knee stability without skin graft.



Conclusion

The gastrocnemius flap appears to be a viable option addressing soft tissue defects and extensor mechanism loss, consistently delivering positive outcomes. This muscle flap is especially indicated in infectious scenarios and revision surgeries, offering efficient extensor mechanism reconstruction with minimal donor site morbidity in non-athletic patients.